



# CUA Best-Practice Report: Diagnosis and Management of Radiation-induced Hemorrhagic Cystitis

George Goucher, MD; Fred Saad, MD; Himu Lukka, MD; Anil Kapoor, MD

Originally published in *Can Urol Assoc J* 2019;13(2):15-23.

<http://dx.doi.org/10.5489/cuaj.5788>



# Disclosures

**Dr. Saad** reports personal fees and research grants from Amgen Inc, Astellas, Bayer, Janssen, and Sanofi.

**Dr. Lukka** is a speaker for Astellas; has received grants and/or honoraria from Abbvie, Actavis, Amgen, Astellas, Bayer, Ferring, Janssen, Sanofi, and Tersera; owns stock and options in Vertex Pharmaceutical; and has participated in clinical trials supported by Bayer and Janssen.

**Dr. Kapoor** has been an advisor for and has participated in clinical trials supported by Amgen, Astellas, GSK, Janssen, Novartis, Pfizer, and Sanofi.



# Definitions

- **Hemorrhagic cystitis** refers to a collection of symptoms and signs defined by hematuria, lower urinary tract symptoms, and cystoscopic findings indicative of underlying urothelial damage.
- It can have a number of underlying causative factors, including treatment with chemotherapeutic agents, such as cyclophosphamide and concurrent therapies, post-transplant patients, infection-mediated, as well as treatment with **radiation therapy**.
- **Radiation-induced hemorrhagic cystitis (RHC)** is often an adverse event in patients with previous radiation to the pelvis for urological or gynecological malignancy and is the focus of this best practice report.



# Background

- Radiation-induced hemorrhagic cystitis is a complex condition with a paucity of high-level evidence to guide treatment decisions.
- This best practice report provides suggestions for management according to different clinical states and presentations:
  - Initial management (including diagnosis and assessment)
  - Persistent or recurrent clinically significant hematuria
  - Life-threatening and refractory hematuria
- These slides summarize recommendation statements from the best practice report. A detailed explanation with supporting evidence can be found in the journal article.



# CUA guidelines

## LEVEL OF EVIDENCE

- Level 1.** Meta-analysis of RCTs or a good-quality RCT\*
- Level 2.** Low-quality RCT or meta-analysis of good-quality prospective cohort studies
- Level 3.** Good-quality retrospective case-control studies or case series
- Level 4.** Expert opinion based on “first principles” or bench research, not on evidence

## GRADES OF RECOMMENDATION

- Grade A.** Usually consistent level 1 evidence
- Grade B.** Consistent level 2 or 3 evidence or “majority evidence” from RCT’s
- Grade C.** Level 4 evidence, “majority evidence” from level 2 or 3 studies, expert opinion
- Grade D.** No recommendation possible because of inadequate or conflicting evidence



# Initial management

- Assessment of a patient complaining of hematuria post-radiation therapy should identify or exclude other pathologic factors that may explain or contribute to the patients symptoms (**Grade 4C**).
- All patients with hematuria should undergo at least one initial cystoscopy with or without fulguration of suspect lesions and biopsy of any lesions concerning for malignancy for diagnostic and therapeutic purposes (**Grade 3C**).
- Laser therapy and endoscopic use of hemostatic agents may play a role in early management of RHC but insufficient data exists to evaluate their efficacy and safety, and long-term followup is needed prior to any recommendations being made (**Grade 3D**).



# Persistent or recurrent clinically significant hematuria

## Intravesical agents:

- Irrigation with alum is a practical and easily applied treatment for radiation-induced hemorrhagic cystitis with a comparatively acute onset of action that is generally well tolerated. Special caution should be used in patients with poor renal function (**Grade 3C**).
- Intravesical therapy with hyaluronic acid may improve symptoms of RHC, and may provide further benefit in those with significant LUTS. Its slow onset of action and lack of research in severe hematuria may limit its usefulness in the acute or in-patient setting (**Grade 3C**).
- Several [other] intravesical options have been trialed in limited case series, but require replication, etiology-specific assessment, or comparative data before they can be formally included as recommendations (**Grade 3D**).



# Persistent or recurrent clinically significant hematuria

## Systemic agents:

- Multiple studies have demonstrated that hyperbaric oxygen therapy is safe and effective and should be considered an early treatment option for RHC in patients who have failed cystoscopy and fulguration. Due to significant resource and expertise requirements, its use may be limited based on access and availability (**Grade 3C**).
- Several case series have shown a potential reduction of hematuria with treatment with sodium pentosan polysulfate in patients with RHC. It is safe and generally well-tolerated, although the slow onset of action may limit its usefulness in treatment of acute or severe RHC (**Grade 3C**).
- Multiple [other] systemic agents have been used in small experimental situations for treatment of radiation-induced hemorrhagic cystitis, until further studies are completed no formal recommendations can be made regarding their use (**Grade 3D**).





# Refractory and life-threatening hematuria

## Trans-arterial embolization:

- Trans-arterial embolization is a viable option for control of radiation-induced hematuria in those whom less invasive methods have been unsuccessful. Preference should be given to selective, or super-selective embolization when available to lessen possible side effects **(Grade 3C)**.

## Formalin:

- Due to significant morbidity associated with the procedure, formalin instillations should only be used in those who have failed less invasive treatments. If treatment is necessary, all attempts should be made to prevent reflux into the upper tracts and the patient needs careful monitoring for potential side effects **(Grade 3C)**.



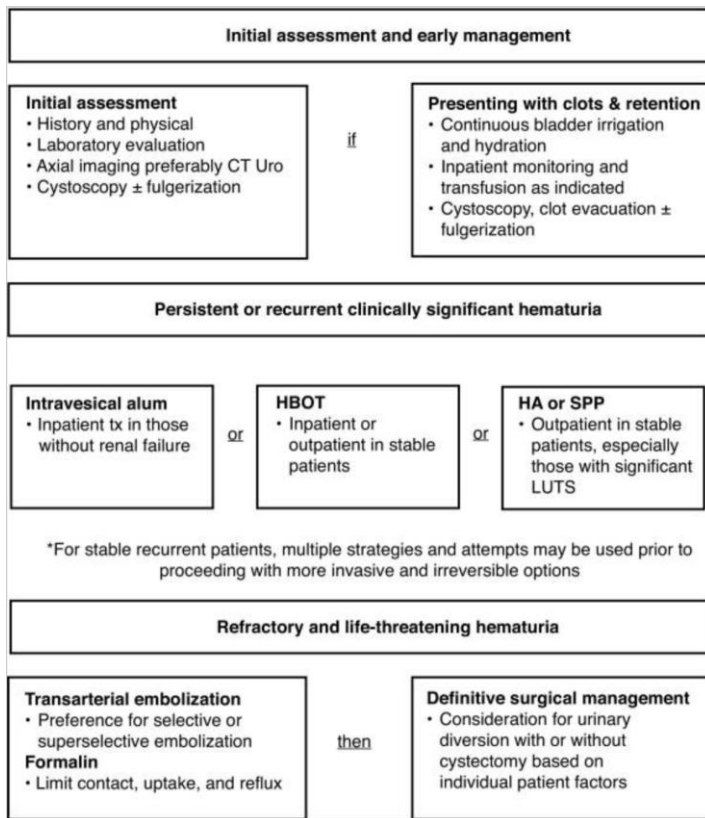
# Refractory and life-threatening hematuria

## Urinary diversion with or without cystectomy:

- Urinary diversion with or without cystectomy for RHC should be reserved only for those who have failed previously available therapy, and clinicians and patients should both be aware of the high morbidity and mortality of the procedure before proceeding with surgery **(Grade 3C)**.



# Suggested algorithm





# Conclusions

- Radiation-induced hemorrhagic cystitis remains a challenging medical condition that often presents in a frail and vulnerable population.
- In this report, we have presented a general approach and suggestions for management, as well as an overview of key research supporting specific therapies.
- These guidelines should always be used in the context of an individual patient's presentation and may continue to evolve as more evidence is available on the subject.